# Hyperbaric oxygen therapy promotes wound repair in ischemic and hyperglycemic conditions, increasing tissue perfusion and collagen deposition

Dominik André-Lévigne, MD, PhD[1]; Ali Modarressi, MD[1]; Rodrigue Pignel, MD[2]; Marie-Luce Bochaton-Piallat, PhD[3]; Brigitte Pittet-Cuénod, MD[1]

1. Division of Plastic, Reconstructive & Aesthetic Surgery, Faculty of Medicine, University Hospitals of Geneva, University of Geneva, Geneva, Switzerland,
2. Division of Hyperbaric Medicine, Department of Health and Community Medicine, University Hospitals of Geneva, Geneva, Switzerland', and
3. Department of Pathology, University of Geneva, Geneva, Switzerland

**Reprint requests:**
D. André-Lévigne, MD, PhD, Division of Plastic, Reconstructive & Aesthetic Surgery, University Hospitals of Geneva (HUG), Rue Gabrielle-Perret-Gentil 4, 1211 Geneva 14, Switzerland.
Tel: +41 798 626 777;
Fax: +41 22 3728005;
Email: dominik@levigne.eu

Manuscript received: March 9, 2016
Accepted in final form: September 3, 2016

DOI:10.1111/wrr.12480



## ABSTRACT

The treatment of chronic wounds remains inconsistent and empirical. Hyperbaric oxygen therapy (HBOT) is a promising method to improve wound repair but there is still a lack of understanding of its mechanisms of action and its indications are not yet clearly defined. We studied the effects of HBOT in four different wound conditions by inflicting bilateral wounds on the dorsal aspect of the feet of nonischemic or ischemic limbs in normoglycemic or hyperglycemic rats. To create an ischemic condition, arterial resection was performed unilaterally. Forty-four animals received HBOT five times a week until complete wound closure. Wound repair was compared with 44 rats receiving standard dressing only. HBOT increased blood flow and accelerated wound closure in ischemic and hyperglycemic wounds, most significantly when the two conditions were combined. Wound contraction and reepithelialization were similarly stimulated by HBOT. The acceleration of wound contraction was not associated with increased myofibroblasts expression, nor fibroblast recruitment or higher cell count in the granulation tissue. Of note, we observed a significant increase in collagen deposition in early time points in ischemic wounds receiving HBOT. This data emphasizes that an early application of HBOT might be crucial to its efficacy. We concluded that wounds where ischemia and hyperglycemia are combined, as it is often the case in diabetic patients, have the best chance to benefit from HBOT.

Chronic wounds become increasingly frequent due to the rise of diabetes mellitus. Their therapy remains inconsistent and empirical, lacking knowledge of pathophysiological mechanisms and exact indications.[1] Given the fact that prolonged ischemia results in impeded wound repair and that chronic wounds often show some degree of ischemia, the idea of treating chronic wounds with either topically or systemically administered oxygen has a long history.[2]

Oxygen serves as a nutrient in oxidative metabolism and is likely to have widespread regulatory functions during wound repair, being the central element of all redox signaling.[3] These universal implications of oxygen during wound repair makes it a promising target to treat chronic wounds.

Hyperbaric oxygen therapy (HBOT) is an effective method to increase oxygen tensions in the wound bed[4–7] and some experimental observations suggest that it could be effectively accelerating wound repair.[2,8–10] Clinical trials have shown that HBOT improves health-related quality of life in patients with chronic diabetic foot ulcer[11] but a recently published clinical trial reported that HBOT does not reduce indications for amputation in patients with diabetes with nonhealing ulcers.[12] There is still insufficient data on its efficacy and its mechanisms of action in promoting wound repair are only partly understood. It is yet unclear which type of wound most likely benefits from such re-oxygenation, resulting in inconsistent treatment protocols and vague indications.

In a recent study, we observed that hyperglycemia exponentially exacerbates the negative effects of ischemia on wound repair, especially on wound contraction and myofibroblast differentiation.[13] Similarly, we found that in vitro, hypoxia suppresses myofibroblast differentiation, and the adverse effects of hypoxia on myofibroblasts can be reversed when reestablishing normal oxygen levels.[14] In vitro studies from other groups suggest that HBOT stimulates fibroblasts proliferation, TGF$\beta$1-secretion and collagen synthesis.[14–16] To our knowledge, the effect of HBOT on myofibroblast differentiation during wound repair has not yet been addressed in vivo. We hypothesized that applying HBOT to ischemic and/or hyperglycemic wounds could restore myofibroblast function and wound contraction.

In the following study, we investigated the effects of HBOT in four different wound conditions: nonischemic

and ischemic wounds in either normoglycemic or hyperglycemic animals. We aimed at elucidating whether HBOT accelerates wound closure and whether it counteracts the negative effects of hyperglycemia and ischemia on wound contraction. Collagen disposition, fibroblast recruitment and myofibroblast differentiation were quantified to address various mechanisms involved in wound contraction. Furthermore, we aimed at establishing which type of wound benefits most from the treatment.

## MATERIALS AND METHODS

### Animal wound model

Our previously described model of ischemic, hyperglycemic wound repair was used to study four different wound conditions[13]: nonischemic and ischemic wounds in normoglycemic and streptozotocin-induced hyperglycemic rats. In normoglycemic rats ($n = 44$), unilateral limb ischemia was induced by resection of the left external iliac and femoral artery. To avoid unduly frequent limb necrosis due to hyperglycemia as described previously,[17] we inflicted a less severe ischemia in hyperglycemic rats ($n = 44$) by resecting only the femoral artery. Subsequently, bilateral wounds were created on the dorsal aspect of the hind feet (see Figure 1a). All animals received a semi-occlusive wound dressing (Tegaderm) that was changed twice a week until complete wound closure.

### Treatment groups

Normoglycemic ($n = 22$) and hyperglycemic ($n = 22$) animals were treated with HBOT. Rats were put inside the hyperbaric chamber in an airtight plastic container equipped with one tube for oxygen and air instillation and one outlet tube, connected to the gas system of the hyperbaric chamber. Treatment sessions were of 95 minutes, consisting of 15 minutes pressure increasing at 100% oxygen, 30 minutes plateau pressures at 2.5ATA at 100% oxygen, 5 minutes at 2.5ATA at 21% oxygen, followed by 100% oxygen for another 30 minutes and 15 minutes decreasing pressure at 100% oxygen. Rats received HBOT five times a week until complete wound closure. Wound repair in these animals was compared with rats receiving standard semi-occlusive dressing only.

### Wound repair assessment

Wound size reduction over time, the time of complete wound closure and the contraction/reepithelialization ratio were assessed. Wound size and aspect were documented immediately after wounding until complete wound closure. Wounds were photographed at a constant distance with a ruler next to the wound for scaling. The wound surface was calculated on photos using a computer-assisted image analysis system (ImageJ).

At complete wound closure (i.e., full epithelialization), the surface of hairless skin of the scar was measured and considered to correspond to the area of the wound which healed by reepithelialization. The surface of the wound healed by contraction was then estimated by subtraction of the epithelialized surface from the wound surface measured at day 0 (see Figure 1e).

Limb necrosis was defined to occur as soon as we macroscopically observed complete necrosis of at least one entire toe. As agreed with the local animal authority before starting the experiments, these animals were immediately sacrificed and excluded from the study.

### Percutaneous laser Doppler measurements

Laser Doppler flowmetry was performed to measure blood flow in the skin using a percutaneous laser Doppler perfusion monitor (PIM II Laser Doppler Perfusion Imager, LDPIwin 2.0.6 software, Lisca AB Berzelius Science Park, Linköping, Sweden). Measurements were carried out on the dorsal surface of the foot, immediately before creation of the ischemic injury (baseline, BL) and during the observation period after the wounding. Results were expressed in arbitrary perfusion units.

### Histology and immunohistochemistry

Rats were sacrificed at days 7, 14, and 21 ($n = 4$ per time point and per group) and the entire foot with the wound and surrounding uninjured skin was harvested. The tissue was fixed in 4% buffered formaldehyde. Hematoxylin/eosin (H/E) staining as well as Masson's trichrome staining and immunohistostaining for α-smooth muscle actin (α-SMA) and vimentin were performed on paraffin-embedded transverse sections.

For immunohistochemical analysis, 4 $\mu$m thick tissue sections from FFPE samples were analyzed using anti-α-SMA (clone 1A4, Dako, #M0851) and anti-vimentin antibody (clone V9, Dako, #M0725) with the Ventana Discovery automated staining system (Ventana Medical Systems, Tucson, AZ). Ventana reagents were used for the entire procedure. No antigen retrieval pretreatment was required for α-SMA staining, for vimentin staining slides were heated 12 minutes in CC1 buffer for antigen retrieval. Slides were incubated 30 minutes at 37 °C with primary antibodies diluted at 1/300 (α-SMA) and 1/40 (vimentin) in antibody diluent from Ventana. Then secondary antibodies were applied at dilution 1/250 (anti-mouse IgG1 + IgG2a + IgG3, abcam, ab133469, 2.03 mg/ml). Detection of secondary antibodies was carried out using the rabbit OmniMap kit (Ventana Medical Systems), based on conversion of diaminobenzidine to a dye with multimeric horseradish peroxidase.

Sections stained with anti-α-SMA were scanned with a Mirax Widefield scanner (brightfield detector: Marlin F-146C IRF Medical). Vimentin-, H/E- and Masson-stained slides were scanned using the Zeiss Axio Scan Z1 Bightfield scanner (Carl Zeiss AG, Germany). Pictures were then processed using Definiens Tissue Studio software (Definiens AG, Munich, Germany). The region of interest (ROI) was manually defined drawing polygons surrounding the entire visible granulation tissue. From the ROI we manually excluded vessels when evaluating the presence of myofibroblasts based on α-SMA expression and the presence of fibroblastic cells based on vimentin staining. Immunostaining was expressed as relative stained area per ROI area (%).

General cellularity was quantified by counting individual nuclei in the manually defined granulation tissue (ROI) and expressed as cells/mm$^2$. Collagen expression in the granulation tissue was quantified by counting the area

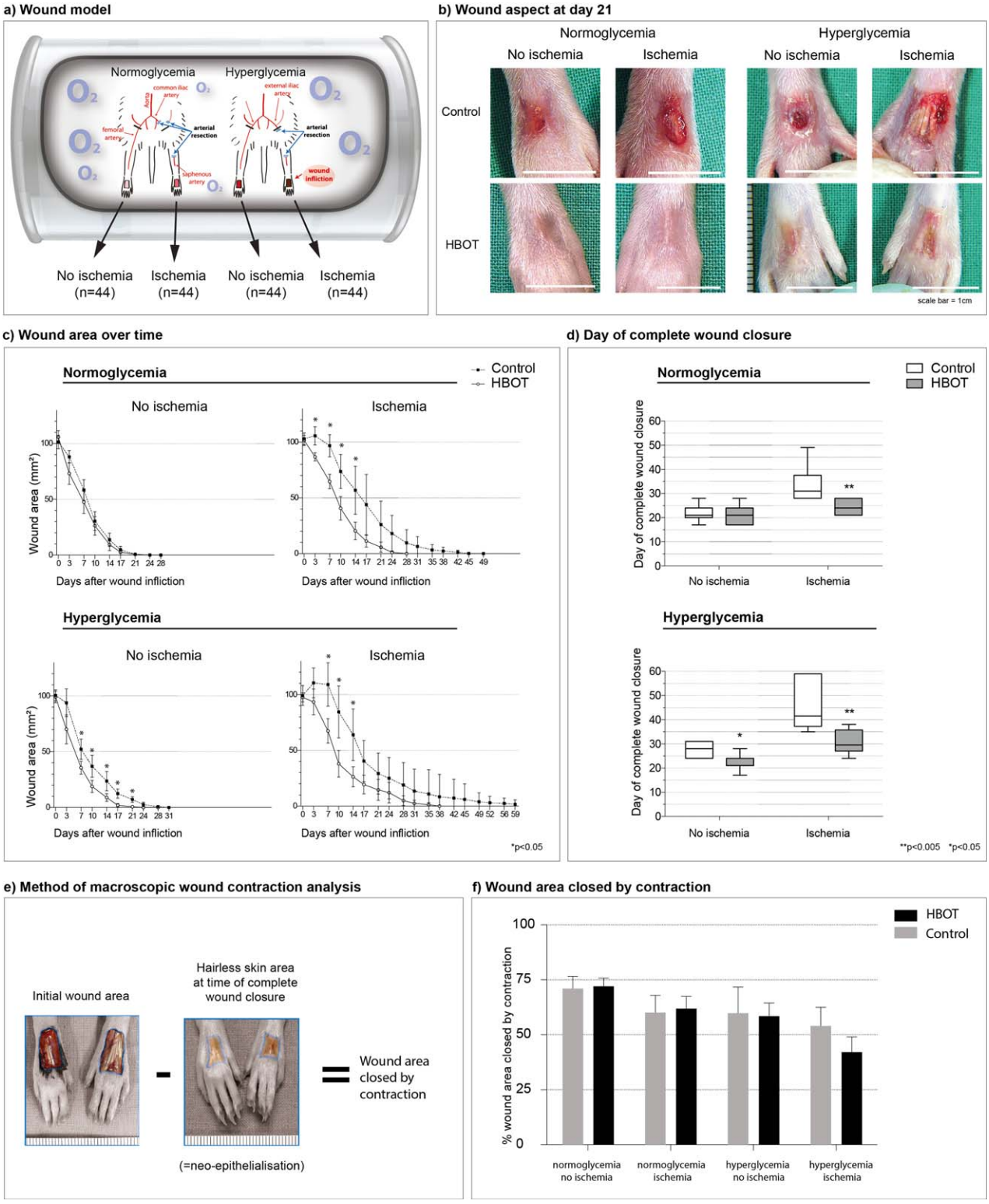
a) Wound model
Normoglycemia
Hyperglycemia
common iliac artery
external iliac artery
Aorta
femoral artery
arterial resection
saphenous artery
wound infliction
No ischemia (n=44)
Ischemia (n=44)
No ischemia (n=44)
Ischemia (n=44)
b) Wound aspect at day 21
Normoglycemia
Hyperglycemia
No ischemia
Ischemia
No ischemia
Ischemia
Control
HBOT
scale bar = 1cm
c) Wound area over time
Normoglycemia
Control
HBOT
No ischemia
Ischemia
Wound area (mm²)
Days after wound infliction
Hyperglycemia
No ischemia
Ischemia
Wound area (mm²)
Days after wound infliction
*p<0.05
d) Day of complete wound closure
Normoglycemia
Control
HBOT
Day of complete wound closure
No ischemia
Ischemia
Hyperglycemia
Day of complete wound closure
No ischemia
Ischemia
**p<0.005 *p<0.05
e) Method of macroscopic wound contraction analysis
Initial wound area
Hairless skin area at time of complete wound closure
Wound area closed by contraction
(=neo-epithelialisation)
f) Wound area closed by contraction
HBOT
Control
% wound area closed by contraction
normoglycemia no ischemia
normoglycemia ischemia
hyperglycemia no ischemia
hyperglycemia ischemia

**Figure 1.**

stained by aniline blue in Masson's trichrome staining within the ROI and expressed as relative stained area per ROI area (%).

### Statistical methods

Values are expressed as the mean ± standard deviation (SD) unless otherwise stated. Data were analyzed with Prism6 software (GraphPad Software, Inc., La Jolla, CA). Statistical analysis consisted in a comparison of data from rats receiving standard wound dressing only with those receiving HBOT, using two-tailed Student's *t* tests for unpaired comparisons between groups. Differences were considered significant at $p < 0.05$. In cases of multiple comparisons, a post hoc correction with the Bonferroni procedure was performed. The Mantel–Cox test was used for comparing the difference between the no-HBOT and the HBOT group in percentage of wounds closed at different time points.

## RESULTS

### Wound aspect

HBOT showed a general tendency toward a beneficial effect in all wound conditions. However, the beneficial effect was most pronounced in ischemic wounds in hyperglycemic animals. The wound aspect in the HBOT group was generally improved with a granulation tissue appearing earlier and the wound size being consistently smaller compared with the control group (see Figure 1b).

### Wound size over time

Ischemia delayed wound closure predominately during early time points whereas hyperglycemia appeared to have an impact on the global kinetics of wound size reduction resulting in a flattening of the wound area curve over time. HBOT counteracted both the delay during early time points due to ischemia (significantly steeper wound size reduction curve at days 3, 7, 10, and 14 in the HBOT group compared with the control group, $p < 0.05$) and the global deceleration due to hyperglycemia (wound size consistently smaller between days 7 and 21 in the HBOT group compared with the control group, $p < 0.05$). HBOT did not significantly modify wound area kinetics in normoglycemic nonischemic conditions compared with the control group (see Figure 1c).

### Time of complete wound closure

In normoglycemic rats HBOT had no effect on the time of complete wound closure of nonischemic wounds (21.5 ± 3.3 days in control animals vs. 21.1 ± 3.6 days in the HBOT group). Ischemic wounds in normoglycemic conditions closed significantly faster when treated with HBOT (33.4 ± 7.6 days in the control group vs. 24.3 ± 2.9 days in the HBOT group, $p < 0.005$).

In hyperglycemic animals, nonischemic wounds closed in 27.3 ± 3.1 days without HBOT. When treated with HBOT, wounds closed significantly faster (22.2 ± 2.9 days, $p < 0.05$). Ischemic wounds in hyperglycemic animals benefited most from HBOT, wounds closing after 30.9 ± 5.3 days compared with 46.2 ± 10.6 days with standard wound dressing ($p < 0.005$) (see Figure 1d).

### Contraction reepithelialization ratio

We observed that the more severe the wound condition got, the less wounds healed by contraction. In untreated animals, wound contraction accounted for 71 ± 6% in nonischemic normoglycemic wounds and only for 54 ± 9% in hyperglycemic, ischemic wounds. When treated with HBOT, hyperglycemic ischemic wounds healed 42 ± 7% by contraction. This tendency toward a shift in favor of reepithelialization rather than contraction in the HBOT group was however not statistically significant. Taken together, HBOT seems not to grossly affect the wound contraction/epithelialization ratio (see Figure 1f).

**Figure 1**. Wound model and macroscopic analysis of wound repair. (a) Experimental model: arterial resection of the external iliac artery was performed in 44 normoglycemic animals, of which 22 received hyperbaric oxygen therapy (HBOT). A less severe ischemia, resecting the femoral artery was induced in 44 hyperglycemic animals, of which 22 received HBOT. (b) Wound aspect 21 days after wound infliction: four different wound conditions are shown, either with or without HBOT. HBOT showed a tendency toward a beneficial effect in all four conditions but it was most pronounced in ischemic wounds of hyperglycemic animals. (c) Wound area over time: wound surface area over time in the different wounds conditions in the control group vs. HBOT. Ischemia predominantly delayed wound healing during early time points while hyperglycemia decelerated the healing process in a global fashion. HBOT significantly accelerated wound size reduction in ischemic and hyperglycemic conditions. The beneficial effect was most pronounced when ischemia and hyperglycemia were combined. Wound areas in $mm^2$, Mean ± SD, $n > 10$ per group, $*p < 0.05$ HBOT vs. control group. (d) HBOT and time of complete wound closure: day of complete wound closure in the four different wound conditions, either with or without HBOT. Nonischemic wounds in normoglycemic animals showed a slight reduction in wound healing time in the HBOT group, although not statistically significant. Wound closure was significantly accelerated in all other groups by the application of HBOT and its beneficial effect was most pronounced in ischemic wounds in hyperglycemic animals. $*p < 0.05$, $**p < 0.005$ HBOT vs. control group, whiskers indicate minimal and maximal values. (e) Calculation of the contraction/epithelialization ratio: the area of the wound is measured directly after surgery. At the day of complete wound closure, the area of hairless skin is measured and considered to correspond to the area of the wound that was closed by reepithelialization. Subtracting the area of reepithelialization from the initial wound area provides the area closed by contraction. (f) Wound area closed by contraction: fraction of the wound closed by contraction in the different wound conditions with or without HBOT. Wounds heal less by contraction as the conditions get more severe. We found a tendency toward a shift in favor of reepithelialization rather than contraction in the HBOT group, not statistically significant. [Color figure can be viewed at wileyonlinelibrary.com]

### Limb necrosis

Following resection of external iliac artery, 27% of normoglycemic animals showed limb necrosis. Twenty-three percent of hyperglycemic animals showed limb necrosis following a less severe resection of the femoral artery. We also found that there was a tendency toward a reduction in limb necrosis when applying HBOT (9% in both hyperglycemic and normoglycemic animals). These results where however not statistically significant ($p = 0.2$ and 0.4 for normoglycemia and hyperglycemia, respectively).

### Limb perfusion

Wound perfusion in nonischemic normoglycemic wounds increased until day 10 after wounding. When treated with HBOT, perfusion rates increased stronger and peaked already at day 7. Perfusion rates at day 7 were significantly higher in the HBOT group compared with the control group ($p < 0.05$).

In normoglycemic animals in ischemic condition, we observed a strong decrease in perfusion following the arterial resection. In untreated animals, perfusion levels reached baseline values at day 7 whereas it took only 3 days for animals receiving HBOT to reach baseline. Perfusion levels were significantly higher with HBOT at days 3, 7, and 10 ($p < 0.005$).

In hyperglycemic animals in nonischemic conditions, we observed an increase in perfusion following wound infliction, but slower than in normoglycemic animals. Maximum perfusion levels were measured at day 21. When treated with HBOT, peak perfusion levels were higher and were reached already at day 7. Perfusion was significantly increased with HBOT at days 3, 7, 10, and 14 ($p < 0.05$).

In hyperglycemic animals in ischemic conditions, perfusion of the limb recovered only slowly and in untreated animals baseline values were reached at day 14. Animals receiving HBOT reached baseline values already at day 3 and showed significantly increased perfusion from days 3 to 21 compared with control wounds ($p < 0.05$; see Figure 2).

### H/E staining and cell count

H/E staining of cross-sections through wounds at days 7, 14, and 21 confirmed our macroscopic results of a significant acceleration of wound repair by HBOT in ischemic and hyperglycemic wounds. The granulation tissue appeared earlier when treated with HBOT and the distance between the wound margins was consistently smaller compared with the untreated wounds.

We quantified the overall cell nucleus count to evaluate whether wound cellularity, including inflammatory cells, as a whole was influenced by the different conditions and by HBOT. We found that the cell count within the granulation tissue was reduced by ischemia and hyperglycemia but was comparable between the HBOT and the control group. At day 21, we observed a tendency toward a reduced cell count in the HBOT group, especially in normoglycemic, nonischemic wounds. However, these wounds were already well closed and therefore in the remodeling phase with the associated cell apoptosis (see Figure 3).

### Vimentin and fibroblastic cell count

We quantified vimentin within the granulation tissue to evaluate whether the different conditions and HBOT influence fibroblast cell recruitment and/or proliferation. Computer-assisted marker quantification of immunohistochemical vimentin staining within the granulation tissue at days 7, 14, and 21 revealed a tendency toward a delay in vimentin expression in hyperglycemic and ischemic wounds compared with normoglycemic nonischemic wounds at day 7 (not statistically significant). In untreated animals at day 21, vimentin expression was higher in hyperglycemic, ischemic wounds compared with normoglycemic, nonischemic wounds ($42.1 \pm 6.6\%$ vs. $12.1 \pm 11.7\%$ of ROI stained, respectively). Similar results were obtained in the HBOT group ($56.4 \pm 4.4\%$ vs. $32.7 \pm 16.5\%$ of ROI stained, respectively). However, no significant difference was observed when comparing the control group to the HBOT group in the respective condition groups. Taken together, we observed a tendency toward a delay in vimentin expression in hyperglycemic and ischemic conditions, but did not observe any significant modification of vimentin expression following HBOT (see Figure 4).

### Alpha-smooth muscle actin and myofibroblast differentiation

We stained wound sections with anti-α-SMA to assess myofibroblast expression in the different groups. Computer-assisted quantification within the granulation tissue at days 7, 14, and 21 revealed that α-SMA expression was significantly lower in ischemic and hyperglycemic wounds compared with nonischemic, normoglycemic wounds ($3.6 \pm 4.3\%$ vs. $20.5 \pm 11.8\%$ of ROI stained, respectively, at day 7 in untreated animals, $p < 0.05$ hyperglycemic ischemic vs. normoglycemic non-ischemic). Similarly, in the HBOT group, hyperglycemic ischemic wounds expressed less α-SMA than normoglycemic, nonischemic wounds ($2.0 \pm 1.7\%$ vs. $19.9 \pm 15.4\%$ of ROI stained, respectively, at day 7 in HBOT animals, $p < 0.05$ hyperglycemic ischemic vs. normoglycemic non-ischemic).

HBOT did not show any significant difference in α-SMA expression when comparing to the control group in the respective condition groups. Very similar staining patterns were observed in treated and untreated wounds in normoglycemic, nonischemic and ischemic conditions with accumulations of myofibroblasts predominately at the wound edge (see Figure 5).

### Masson's trichrome staining and aniline blue quantification

To estimate collagen deposition within the granulation tissue, we quantified the area stained by aniline in Masson's trichrome-colored slides. Computer-assisted quantification of aniline blue within the granulation tissue at days 7, 14, and 21 showed a general tendency toward a reduced collagen presence in the granulation tissue of hyperglycemic and ischemic wounds compared with normoglycemic nonischemic wounds.

When comparing the HBOT and control group in the different conditions, we found a strong tendency toward an increased collagen deposition at all time points and in all

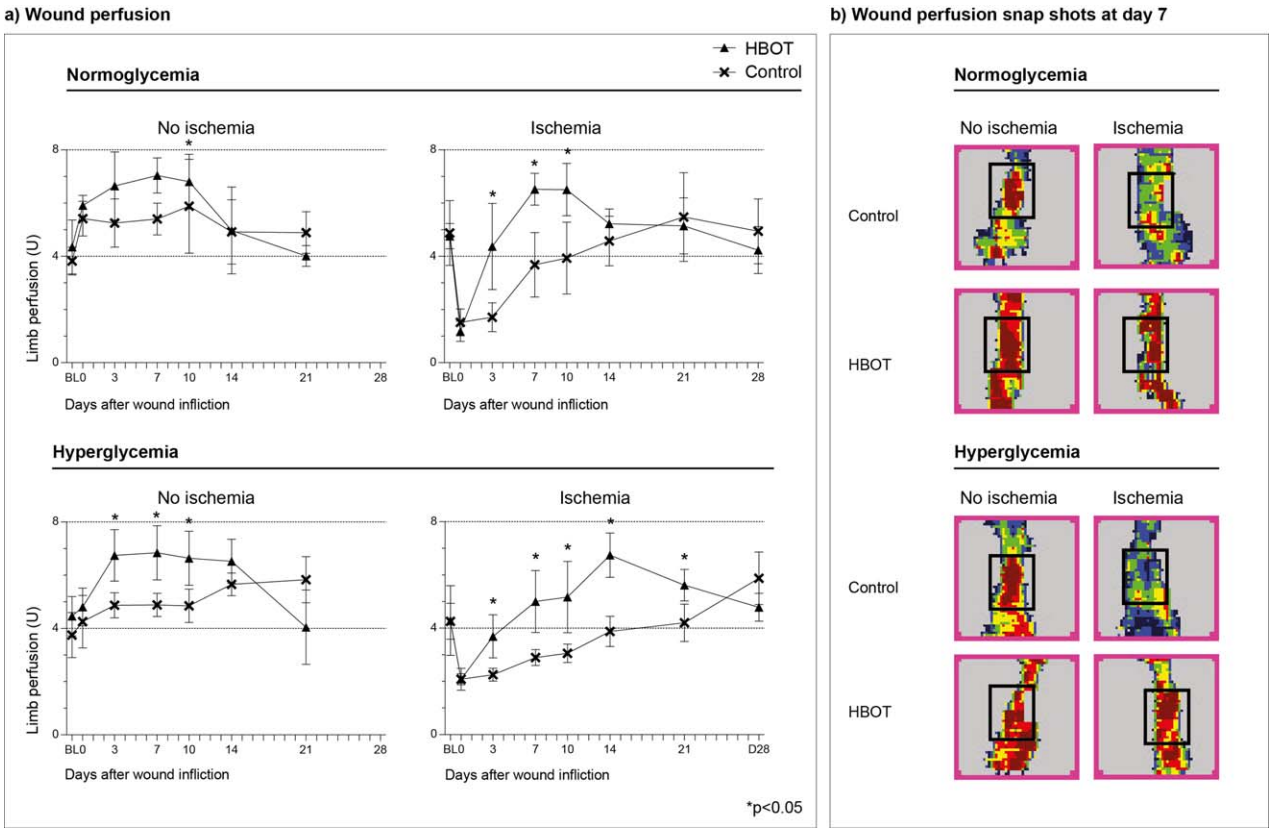


**Figure 2**. Wound blood perfusion. (a) Time course of wound perfusion as measured by laser Doppler imaging. In nonischemic conditions, perfusion was significantly higher in the HBOT group compared with the control group. After arterial resection, perfusion levels reached baseline values earlier when receiving HBOT. In hyperglycemic animals in ischemic conditions, perfusion of the limb recovered only slowly and in untreated animals baseline values were reached on average at day 14. Animals receiving HBOT reached baseline values already at day 3 and showed significantly increased perfusion from days 3 to 21 compared with the control group. Mean ± SD, $n = 6$ per time point, $*p < 0.05$. (b) Wound perfusion snap shots at day 7 in the different groups. Representative views of the laser Doppler machine in the different groups. The black square indicates the area of the food where the wound is located. There was a clear difference in wound perfusion in ischemic conditions at day 7 between the HBOT and control group. [Color figure can be viewed at wileyonlinelibrary.com]

conditions. Especially during early time points (7 days), we demonstrated a statistically significant higher collagen deposition at day 7 in the HBOT group compared with untreated groups in ischemic wounds both in normoglycemic and hyperglycemic conditions (in ischemic normoglycemic wounds 13.0 ± 3.6% of ROI stained in the HBOT group vs. 2.5 ± 2.0% in the control group; in ischemic hyperglycemic wounds 10.1 ± 2.9% of ROI stained in the HBOT group vs. 1.1 ± 0.8% in the control group; $p < 0.05$ HBOT vs. control groups, respectively). Interestingly, in untreated animals, collagen was significantly reduced in ischemic wounds compared with nonischemic wounds. On the contrary, in the HBOT group, collagen quantity in ischemic wounds did not change compared with nonischemic wounds receiving HBOT.

Taken together, ischemia delayed collagen deposition, especially when combined with hyperglycemia and most significantly during early time points. HBOT significantly counteracted these negative effects of ischemia on collagen deposition (see Figure 6).

## DISCUSSION

In this study, we confirmed our previous observations on the negative effects of hyperglycemia and ischemia on wound repair and myofibroblast activity.[13] We observed that HBOT is able to counteract the negative effects on wound closure, significantly accelerating the healing process in ischemic and hyperglycemic conditions, especially when these conditions where combined. We found that HBOT significantly increases blood perfusion rates in the wound area and we observed a tendency toward a decreased occurrence of limb necrosis following arterial resection. HBOT did not significantly alter the contraction/reepithelialization ratio, promoting both mechanisms similarly. Interestingly, the accelerated wound contraction was

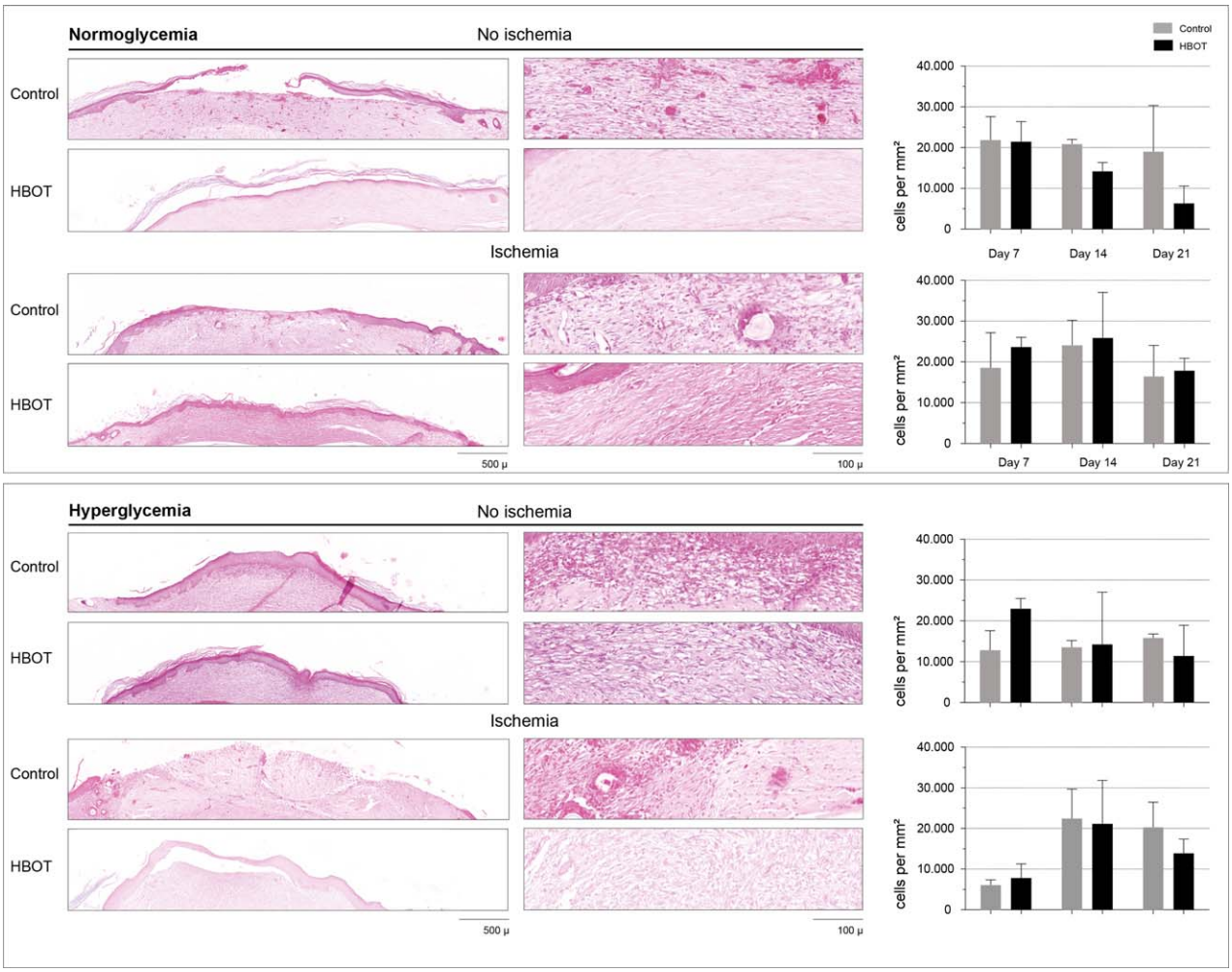


**Figure 3**. H/E staining and nucleus quantification. (Left column) shows representative views of H/E stained cross-sections through wounds at day 21 in the different wound conditions in the HBOT and control group. Note that wounds are further closed in the HBOT group compared with the control group in all wound conditions. Untreated hyperglycemic ischemic wounds are completely open and the epithelial margins are visible in the very corners of the image with the rest of the granulation tissue being uncovered. (Middle column) shows a magnification of the respective slide in the same row. The aspect of the granulation tissue with regards to cell count is comparable with the exception of normoglycemic, nonischemic wounds where the cells are more scarce in the HBOT group compared with the control group. (Right column) shows the results of computer-assisted nucleus quantification within the granulation tissue at days 7, 14, and 21. No significant differences were observed between the HBOT and the control group. The strong tendency toward a decreased cell count at day 21 in the normoglycemic, nonischemic group can be explained by the fact that these wounds are already well advanced in the remodeling phase with the associated cell apoptosis. Mean ± SD, $n = 4$ for each group and time point. [Color figure can be viewed at wileyonlinelibrary.com]

not associated with a significantly increased number of myofibroblasts. To evaluate whether HBOT has an effect on fibroblastic cell recruitment into the wound in general, we quantified vimentin expression in the granulation tissue and found that vimentin staining was not modified by the application of HBOT either. This data suggests that the beneficial effect of HBOT is not due to accelerated fibroblast recruitment into the wound. We hypothesized that HBOT might accelerate wound contraction by increasing collagen deposition. When quantifying aniline blue in the granulation tissue we found that hyperglycemia and ischemia impedes collagen deposition in early time points and that HBOT effectively counteracted this negative effect of ischemia on collagen deposition compared with the control group.

In untreated-wounds, the fraction of the wound closed by reepithelialization increased in ischemic and hyperglycemic conditions, suggesting that it compensates for the lack of contraction. This is consistent with our earlier findings.[13] HBOT did not significantly influence the ratio between wound reepithelialization and contraction; both were strongly and similarly accelerated, suggesting that

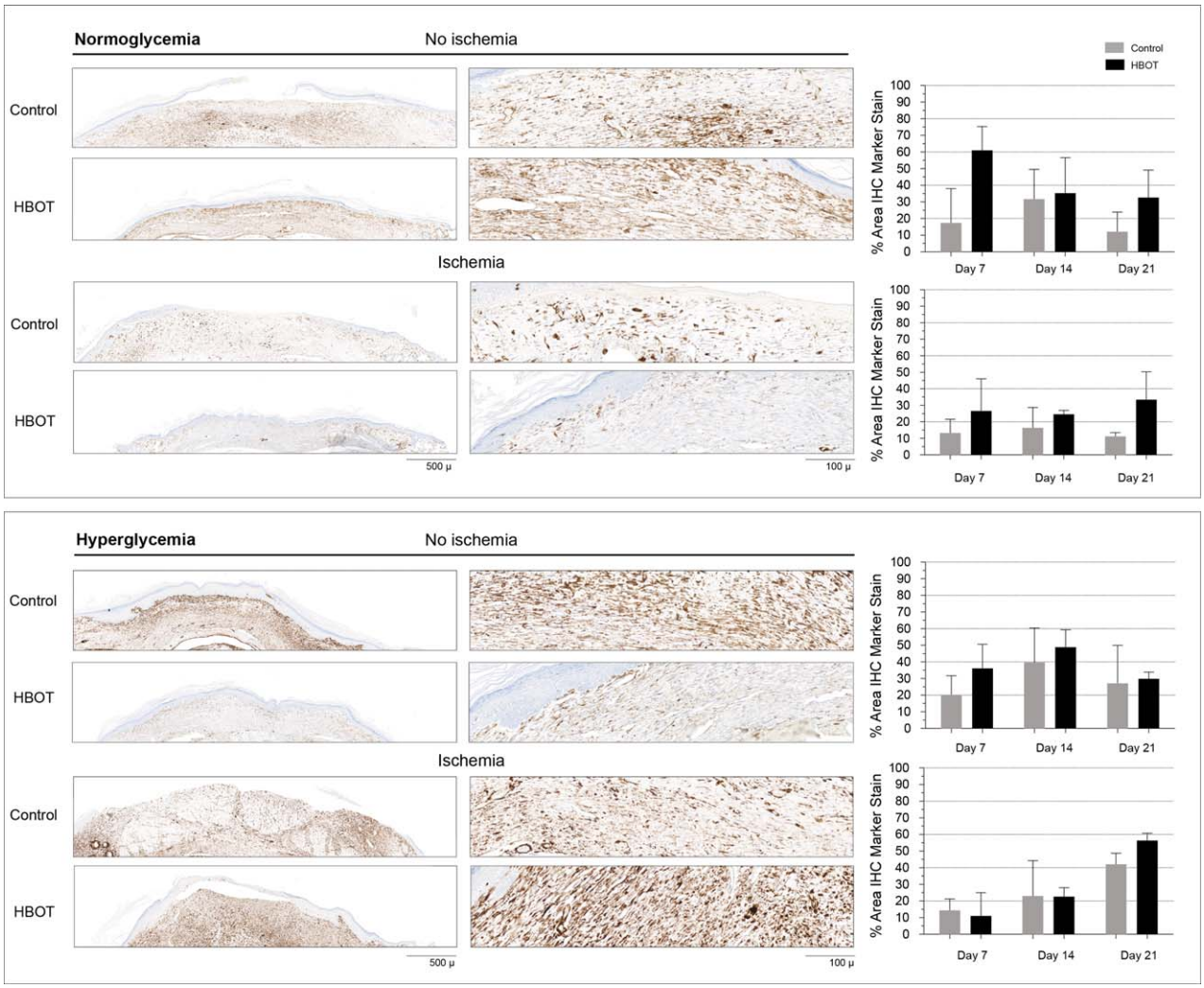


**Figure 4**. Vimentin staining. (Left column) shows representative views of vimentin stained immunohistochemistry cross-sections through wounds at day 21 in the different wound conditions in the HBOT and control group. (Middle column) shows a magnification of the respective slide in the same row. (Right column) shows the results of computer-assisted marker quantification within the granulation tissue at days 7, 14, and 21. Vessels were manually excluded from marker quantification based on their typical morphology. No significant differences were observed between the HBOT and control group. Mean ± SD, $n = 4$ for each group and time point. [Color figure can be viewed at wileyonlinelibrary.com]

HBOT acted in a global manner on wound healing. This is conceivable when taking into consideration the multifaceted and ubiquitous implications of oxygen during wound repair. The effects of HBOT on wound repair are likely to be multifactorial as many crucial growth factors are relying on redox signaling, including platelet derived growth factor,[18] VEGF,[19] epidermal growth factor,[20,21] and keratinocyte growth factor.[22] A recent in vivo study involving a model of impaired wound healing through macrophage depletion showed that HBOT effectively promotes wound epithelialization and neovascularization and suggests that this beneficial effect is due to stimulation of tumor necrosis factor alpha.[23] The notion that HBOT promotes reepithelialization is also supported by earlier studies reporting that HBOT stimulates keratinocytes, accelerates cornification, and keratinocyte migration in a model of three-dimensional human skin-equivalent.[24]

The main aim of this study was to investigate the repercussions of HBOT on wound contraction and its underlying mechanisms in the different wound conditions. We observed that ischemia slowed down wound closure predominately during early time points (days 3–10), leading even to an increase in wound size during the first 3 days in ischemic wounds, consistent with our previous observations,[13] and with those of other groups.[25] When treated with HBOT, no increase in wound size was seen after wound infliction in ischemic wounds and granulation tissue appeared earlier. This is consistent with earlier studies

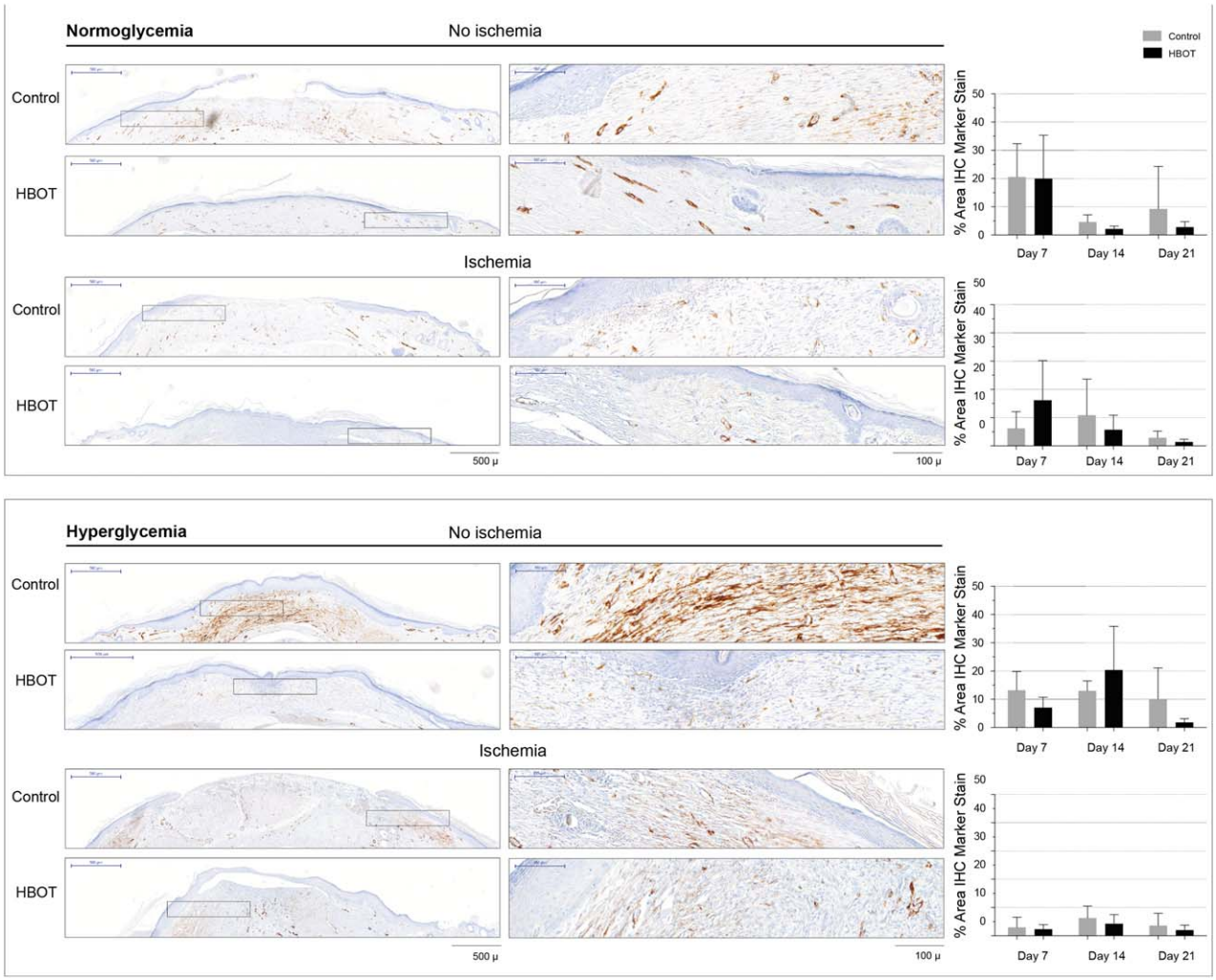


**Figure 5**. Myofibroblast expression. (Left column) shows representative views of α-SMA stained immunohistochemistry cross-sections through wounds at day 21 in the different wound conditions in the HBOT and control group. (Middle column) shows a magnification of the respective slide in the same row. (Right column) shows the results of computer-assisted marker quantification within the granulation tissue at days 7, 14, and 21. Vessels were manually excluded from marker quantification based on their typical morphology. Expressions were significantly lower in ischemic and hyperglycemic wounds compared with nonischemic, normoglycemic wounds. However, no significant differences were observed between the control and HBOT groups. Mean ± SD, $n = 4$ for each group and time point. [Color figure can be viewed at wileyonlinelibrary.com]

that reported that HBOT improves granulation tissue formation,[9,10] and collagen mRNA production and synthesis in a rat wound repair model.[26] In this study, we demonstrated that HBOT is capable of counteracting the negative effects of ischemia on early collagen deposition during wound repair, observing significantly stronger aniline coloration in the granulation tissue at day 7 in wounds treated with HBOT. Adequate oxygen supply is crucial for granulation tissue formation, and collagen deposition rates in the wound have been reported to be directly proportional to tissue oxygen tensions.[27] A rapid deposition of collagen matrix prevents the wound edges from drifting apart and constitutes the basis for wound contraction. It is conceivable that hypoxia at early stages during wound repair leads to a delay in collagen deposition and hence a lack of fixation of the wound edges to underlying layers, facilitating the increase in wound size. These results suggest that an early application of HBOT might be crucial to its efficacy. Mixed results from clinical trials might be due to the fact that HOBT is often applied at a very late stage during wound management.

Surprisingly, the acceleration of wound contraction was not associated with a significant increase in the number of myofibroblasts, indicating that HBOT accelerates wound contraction in a myofibroblast-independent manner. We observed that wound contraction and the presence of myofibroblast do not always coincide. A large proportion of wound contraction in all groups occurs before the

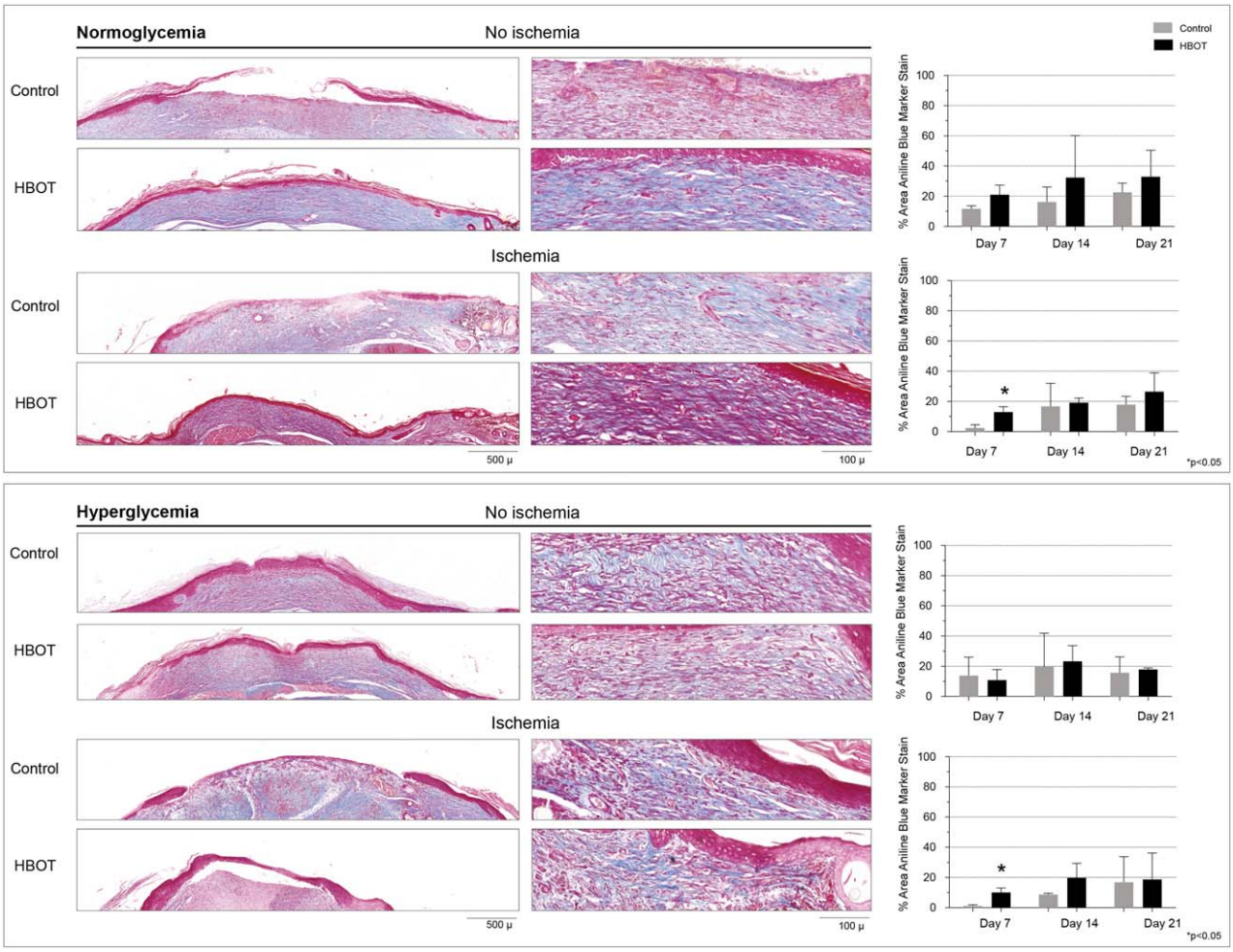


**Figure 6**. Masson's trichrome staining and aniline blue quantification. (Left column) shows representative views of Masson's trichrome stained cross-sections through wounds at day 21 in the different wound conditions in the HBOT and control group. (Middle column) shows a magnification of the respective slide in the same row. (Right column) shows the results of computer-assisted nucleus quantification of aniline blue within the granulation tissue at days 7, 14, and 21. At day 7, aniline staining was significantly weaker in ischemic and hyperglycemic wounds compared with nonischemic, normoglycemic wounds, indicating a collagen deposition delay. In ischemic conditions, HBOT significantly counteracted this negative effect showing significantly higher values at day 7 compared with the control group. Mean ± SD, $n = 4$ for each group and time point, $*p < 0.05$ HBOT vs. control group. [Color figure can be viewed at wileyonlinelibrary.com]

appearance of α-SMA in the granulation tissue. One possible explanation could be that proto-myofibroblasts are contracting the wound. Current theories suggest that proto-myofibroblasts, which are α-SMA negative cells, express much weaker contractile forces than fully differentiated myofibroblasts.[28] However, recent literature suggests that α-SMA expression may not be required for effective wound contraction. In an α-SMA knockout model wound contraction was unimpaired and it was suggested the expression of γ-SMA (a smooth muscle actin mainly found in enteric tissues) can compensate for a lack of α-SMA.[29] Consistently, it has been reported that wound contraction is unimpaired when the Smad signaling pathway is blocked.[30] It has been also suggested that wound contraction is mediated by fibroblasts generating thicker collagen fibers, using tractional forces, rather than by myofibroblasts utilizing cell contraction forces.[31] We hypothesized that HBOT might promote fibroblastic recruitment to the wound bed and promote wound contraction by increasing the number of proto-myofibroblasts, rather than myofibroblasts. However, we did not observe a significant increase in vimentin-positive cells in the granulation tissue by HBOT and the general cell count based on nucleus quantification was not modified either by HBOT.

Hyperglycemia delayed wound closure in a global manner resulting in a flattening of the wound area reduction curve over time. When ischemia and hyperglycemia were combined, we saw a strong delay during early time points with an increase in the wound area during the first week and a significant flattening of the wound size reduction

curve. When treated with HBOT, the curve of wound size reduction steepened significantly in hyperglycemic animals, both in ischemic and nonischemic wounds. HBOT significantly reduced the time needed until complete wound closure and the benefit of HBOT for wound closing was most pronounced in ischemic wounds in hyperglycemic animals. These results suggest that the beneficial effects of HBOT are not limited to counteracting ischemia but that it also directly counteracts the negative effects of hyperglycemia. In diabetic conditions, a multitude of signaling pathways crucial for wound repair is impaired. For instance, the lack of insulin-like growth factor 1 (IGF-1) in diabetic patients has been associated with delayed healing[32] and IGF-1 has been shown to be increased in diabetic foot ulcer receiving HBOT.[33] This could be an interesting topic for future studies on the mechanisms of action of HBOT in diabetic conditions.

HBOT increased wound bed perfusion in all four wound conditions. In ischemic conditions, HBOT significantly reduced the time needed to reestablish baseline perfusion levels after arterial resection, reducing the time the wounds were exposed to ischemia. These findings are in agreement with the report of Sheikh et al. where an increased microvascular perfusion measured by laser Doppler imaging of nonischemic wounds created on the back of mice was observed.[34] Another study showed that angiogenesis into implanted Matrigel plugs in a mouse model was increased by HBOT.[35] HBOT of tissue-engineered mucosa enhanced secretion of vascular endothelial growth factor (VEGF) and hypoxia inducible factor 1$\alpha$ (HIF1$\alpha$) in vitro and wound fluid analysis in rats showed increased levels of VEGF following HBOT.[36,37] The notion that hyperoxia induces HIF1$\alpha$ expression seems counterintuitive at first. However, it has been shown that relative changes of oxygen availability, rather than steady-state hypoxic or hyperoxic conditions, trigger HIF transcriptional effects.[38] The intermittent nature of HBOT could hence be of particular importance for promoting angiogenesis. Further studies should investigate the importance of the intermittent nature of HBOT on neo-angiogenesis and HIF1$\alpha$-VEGF expression.

Our previous studies have shown that hyperglycemia increases the susceptibility to ischemic limb necrosis following arterial resection.[17] In this study, we observed a tendency toward a decreased rate of ischemic necrosis when treated with HBOT, although not statistically significant. Evaluating the benefit of HBOT in critical limb ischemia should be the subject to further studies, possibly using a more severe model of ischemia.

## CONCLUSIONS

HBOT significantly accelerated wound repair, particularly when ischemia and hyperglycemia were combined. HBOT is therefore a very interesting approach for wounds in diabetic patients where both conditions are often present. We found that HBOT significantly increases blood perfusion rates in the wound area and we observed a tendency toward a decreased occurrence of limb necrosis following arterial resection. We demonstrated that wound neo-epithelialization and contraction were both promoted by HBOT. However, the acceleration of wound contraction was not associated with an increase in fibroblastic cell recruitment nor myofibroblast differentiation. Of note, we observed a significant increase in collagen deposition during early time points in wounds receiving HBOT compared with standard wound dressing only. This data emphasizes that an early application of HBOT could be crucial to its efficacy.

## REFERENCES

1. Boateng JS, Matthews KH, Stevens HN, Eccleston GM. Wound healing dressings and drug delivery systems: a review. *J Pharm Sci* 2008; 97: 2892–923.
2. Howard MA, Asmis R, Evans KK, Mustoe TA. Oxygen and wound care: a review of current therapeutic modalities and future direction. *Wound Repair Regen* 2013; 21: 503–11.
3. Eisenbud DE. Oxygen in wound healing: nutrient, antibiotic, signaling molecule, and therapeutic agent. *Clin Plast Surg* 2012; 39: 293–310.
4. Mathieu D. Role of hyperbaric oxygen therapy in the management of lower extremity wounds. *Int J Low Extrem Wounds* 2006; 5: 233–35.
5. Goldman RJ. Hyperbaric oxygen therapy for wound healing and limb salvage: a systematic review. *PM R* 2009; 1: 471–89.
6. Gordillo GM, Sen CK. Evidence-based recommendations for the use of topical oxygen therapy in the treatment of lower extremity wounds. *Int J Low Extrem Wounds* 2009; 8: 105–11.
7. Siddiqui A, Davidson JD, Mustoe TA. Ischemic tissue oxygen capacitance after hyperbaric oxygen therapy: a new physiologic concept. *Plast Reconstr Surg* 1997; 99: 148–55.
8. Feldman-Idov Y, Melamed Y, Ore L. Improvement of ischemic non-healing wounds following hyperoxygenation: the experience at Rambam-Elisha Hyperbaric Center in Israel, 1998–2007. *Isr Med Assoc J* 2011; 13: 524–9.
9. Zhao LL, Davidson JD, Wee SC, Roth SI, Mustoe TA. Effect of hyperbaric oxygen and growth factors on rabbit ear ischemic ulcers. *Arch Surg* 1994; 129: 1043–49.
10. Said HK, Hijjawi J, Roy N, Mogford J, Mustoe T. Transdermal sustained-delivery oxygen improves epithelial healing in a rabbit ear wound model. *Arch Surg* 2005; 140: 998–1004.
11. Londahl M, Landin-Olsson M, Katzman P. Hyperbaric oxygen therapy improves health-related quality of life in patients with diabetes and chronic foot ulcer. *Diabet Med* 2011; 28: 186–90.
12. Fedorko L, Bowen JM, Jones W, Oreopoulos G, Goeree R, Hopkins RB, et al. Hyperbaric oxygen therapy does not reduce indications for amputation in patients with diabetes with nonhealing ulcers of the lower limb: a prospective, double-blind, randomized controlled clinical trial. *Diabet Care* 2016; 39: 392–9.
13. Tobalem M, Levigne D, Modarressi A, Atashi F, Villard F, Hinz B, et al. Hyperglycemia interacts with ischemia in a synergistic way on wound repair and myofibroblast differentiation. *Plast Reconstr Surg Glob Open* 2015; 3: e471.
14. Modarressi A, Pietramaggiori G, Godbout C, Vigato E, Pittet B, Hinz B. Hypoxia impairs skin myofibroblast differentiation and function. *J Invest Dermatol* 2010; 130: 2818–27.
15. Kang TS, Gorti GK, Quan SY, Ho M, Koch RJ. Effect of hyperbaric oxygen on the growth factor profile of fibroblasts. *Arch Facial Plast Surg* 2004; 6: 31–5.
16. Hunt TK, Pai MP. The effect of varying ambient oxygen tensions on wound metabolism and collagen synthesis. *Surg Gynecol Obstet* 1972; 135: 561–7.

17. Levigne D, Tobalem M, Modarressi A, Pittet-Cuenod B. Hyperglycemia increases susceptibility to ischemic necrosis. *BioMed Res Int* 2013; 2013: 490964.
18. Bae YS, Sung JY, Kim OS, Kim YJ, Hur KC, Kazlauskas A, et al. Platelet-derived growth factor-induced H(2)O(2) production requires the activation of phosphatidylinositol 3-kinase. *J Biol Chem* 2000; 275: 10527–31.
19. Abid MR, Tsai JC, Spokes KC, Deshpande SS, Irani K, Aird WC. Vascular endothelial growth factor induces manganese-superoxide dismutase expression in endothelial cells by a Rac1-regulated NADPH oxidase-dependent mechanism. *FASEB J* 2001; 15: 2548–50.
20. Goldkorn T, Balaban N, Matsukuma K, Chea V, Gould R, Last J, et al. EGF-receptor phosphorylation and signaling are targeted by $H_2O_2$ redox stress. *Am J Respir Cell Mol Biol* 1998; 19: 786–98.
21. Peus D, Vasa RA, Meves A, Pott M, Beyerle A, Squillace K, et al. $H_2O_2$ is an important mediator of UVB-induced EGF-receptor phosphorylation in cultured keratinocytes. *J Invest Dermatol* 1998; 110: 966–71.
22. Marchese C, Maresca V, Cardinali G, Belleudi F, Ceccarelli S, Bellocci M, et al. UVB-induced activation and internalization of keratinocyte growth factor receptor. *Oncogene* 2003; 22: 2422–31.
23. Sander AL, Henrich D, Muth CM, Marzi I, Barker JH, Frank JM. *In vivo* effect of hyperbaric oxygen on wound angiogenesis and epithelialization. *Wound Repair Regen* 2009; 17: 179–84.
24. Kairuz E, Upton Z, Dawson RA, Malda J. Hyperbaric oxygen stimulates epidermal reconstruction in human skin equivalents. *Wound Repair Regen* 2007; 15: 266–74.
25. Roy S, Biswas S, Khanna S, Gordillo G, Bergdall V, Green J, et al. Characterization of a preclinical model of chronic ischemic wound. *Physiol Genomics* 2009; 37: 211–24.
26. Ishii Y, Miyanaga Y, Shimojo H, Ushida T, Tateishi T. Effects of hyperbaric oxygen on procollagen messenger RNA levels and collagen synthesis in the healing of rat tendon laceration. *Tissue Eng* 1999; 5: 279–86.
27. Jonsson K, Jensen JA, Goodson WH, 3rd, Scheuenstuhl H, West J, Hopf HW, et al. Tissue oxygenation, anemia, and perfusion in relation to wound healing in surgical patients. *Ann Surg* 1991; 214: 605–13.
28. Tomasek JJ, Gabbiani G, Hinz B, Chaponnier C, Brown RA. Myofibroblasts and mechano-regulation of connective tissue remodelling. *Nat Rev Mol Cell Biol* 2002; 3: 349–63.
29. Tomasek JJ, Haaksma CJ, Schwartz RJ, Howard EW. Whole animal knockout of smooth muscle alpha-actin does not alter excisional wound healing or the fibroblast-to-myofibroblast transition. *Wound Repair Regen* 2013; 21: 166–76.
30. Au K, Ehrlich HP. When the Smad signaling pathway is impaired, fibroblasts advance open wound contraction. *Exp Mol Pathol* 2010; 89: 236–40.
31. Ehrlich HP, Hunt TK. Collagen organization critical role in wound contraction. *Adv Wound Care* 2012; 1: 3–9.
32. Blakytny R, Jude EB, Martin Gibson J, Boulton AJ, Ferguson MW. Lack of insulin-like growth factor 1 (IGF1) in the basal keratinocyte layer of diabetic skin and diabetic foot ulcers. *J Pathol* 2000;190 (5):589–594.
33. Aydin F, Kaya A, Karapinar L, Kumbaraci M, Imerci A, Karapinar H, et al. IGF-1 increases with hyperbaric oxygen therapy and promotes wound healing in diabetic foot ulcers. *J Diabetes Res* 2013; 2013: 567834.
34. Sheikh AY, Rollins MD, Hopf HW, Hunt TK. Hyperoxia improves microvascular perfusion in a murine wound model. *Wound Repair Regen* 2005; 13: 303–8.
35. Hopf HW, Gibson JJ, Angeles AP, Constant JS, Feng JJ, Rollins MD, et al. Hyperoxia and angiogenesis. *Wound Repair Regen* 2005; 13: 558–64.
36. Tra WM, Spiegelberg L, Tuk B, Hovius SE, Perez-Amodio S. Hyperbaric oxygen treatment of tissue-engineered mucosa enhances secretion of angiogenic factors *in vitro*. *Tissue Eng A* 2014; 20: 1523–30.
37. Sheikh AY, Gibson JJ, Rollins MD, Hopf HW, Hussain Z, Hunt TK. Effect of hyperoxia on vascular endothelial growth factor levels in a wound model. *Arch Surg* 2000; 135: 1293–7.
38. Rocco M, D'Itri L, De Bels D, Corazza F, Balestra C. The "normobaric oxygen paradox": a new tool for the anesthetist? *Minerva Anestesiol* 2014; 80: 366–72.